

## Neuro-ophthalmological symptoms in vertigo and dizziness

C. Van Nechel

Neuro-ophthalmological Unit, Erasmus University Hospital, Brussels  
Neurological Department, Brugmann University Hospital, Brussels.  
I.R.O.N., Paris

**Key-words.** Dizziness; vertigo; vestibular function tests; nystagmus; diplopia

**Abstract.** *Neuro-ophthalmological symptoms in vertigo and dizziness.* The vestibular and visual systems are closely linked in the genesis of vertigo and dizziness. An examination of these two systems is helpful in the search for an aetiological diagnosis. In ENT, this double approach can also help to avoid certain ophthalmological pitfalls such as the mistaken idea that a squint cannot be of vestibular origin, that the absence of diplopia symptoms is enough to exclude any recent oculomotor paresis, or even that eyelid asymmetry is not relevant to diagnosing dizziness. This paper is intended to help in understanding the neuro-ophthalmological aspects of the guidelines. It is sometimes limited to defining certain terms. However, on the whole, it covers diagnostic procedures.

### 1. Skew deviation and vertical diplopia of vestibular origin

A vertical diplopia (one image above the other) may be the consequence of a lesion in the vestibular system, including a lesion restricted to the labyrinth. The otolithic system contributes to the control of vertical eye movements and alignment. In mammals with lateral vision, a head tilt induces an upper movement of the ipsilateral eye and a lowering of the contralateral eye. The modification of eye-muscle implantation associated with the shift to frontal vision added a torsional (ocular rotation around the visual axis) action to the vertical muscles. So a head tilt in humans induces a torsional movement of both eyes with an amplitude of a few degrees, the “counter-rolling reflex”. Normally, this reflex does not result in any vertical misalignment between the eyes because of accurate balance in the antagonist vertical eye muscles. A dysfunction in any structure associated with this otolithic reflex, from the

labyrinth to the eye muscles, through the vestibular nuclei and the mesencephalic nuclei of Cajal, can provoke a vertical misalignment with torsion of the eyes and vertical diplopia if the patient has binocular vision. This vertical misalignment with torsion of the eyes consecutive to a lesion of the vestibular system is called “skew deviation”. The lower eye is ipsilateral to a labyrinthic or vestibular nucleus lesion, and contralateral to a lesion located higher on the otolithic pathways. The impairment of the otolithic system means that this skew deviation is often combined with a spontaneous head tilt, body latero-deviation and an error in the estimation of the visual vertical. This complete otolithic syndrome is called “Ocular Tilt Reaction” (OTR).<sup>1</sup>

Horizontal diplopia is never a consequence of a direct lesion of the vestibular system. However, it can result from impaired structures very close to the vestibular pathways and so contribute to the localisation diagnosis.

Let us remember that an ocular misalignment does not necessarily imply diplopia. Monocular amblyopia, alternating fixation or, paradoxically, a significant angle between the ocular axes can eliminate the diplopia. A contralateral head tilt with a normal counter-rolling reflex can also sometimes counteract vertical diplopia.

There are two simple ways of detecting ocular misalignment. The first one consists of observing the reflection of a lamp in both pupils. The position of this reflection should remain relatively stable during gaze deviations. The second consists of placing a coloured filter in front of one of the patient’s eyes. To exclude an eye misalignment, we check that the patient does not see two different points in binocular vision, while one point is indeed seen when we hide each eye. This last method can lead to some false positive results when there is phoria or a lack of binocular fusion. These two techniques will allow for the easy detection of a vertical diplopia.

## 2. Nystagmus

This paper will not provide details about the most likely localisations depending on the manifestations of all the different types of nystagmus. Several syntheses of the contribution of nystagmus to this localisation diagnosis are available.<sup>2,3</sup> From the physiopathological point of view, it should be remembered that, although there are three mechanisms responsible for nystagmus, only the first is of vestibular origin.

### a) Nystagmus associated with impaired vestibulo-ocular reflex

These deficits are characterised by both eyes being “pulled in one direction”, with this movement corresponding to the slow phase of the nystagmus. This direction depends directly on the site of the lesion. The plane orientations of the semicircular canals are close to those of the oculomotor muscles. Each canal has a privileged relation with the muscle that moves the eye in a direction opposite to the head movement stimulating that canal. Ocular muscle implantation precludes a purely vertical eye movement through the stimulation of a single vertical muscle. The movement will always be around a vertical axis associated with a torsional movement of the eyeball. It is reasonable to assume that this association excludes the possibility of nystagmus with a purely vertical or rotatory slow phase caused by a unilateral peripheral lesion. At the central level it is necessary to keep clearly in mind that the conjugate horizontal eye movements are, in

essence, organised at the level of the pons. It is at this level that we find the abducens nucleus (VI), the starting point for the stimulation of the lateral rectus muscle and the ascending pathway (medial longitudinal fasciculus) which stimulates the motoneurons of the medial rectus muscle at the level of the common oculomotor nucleus. Oculomotor nuclei responsible for vertical and torsional eye movements are located higher in the brainstem, at the level of the midbrain. As a result, nystagmus of central origin associated with a lesion situated at the brainstem input level in the vestibular pathways (ponto-medullary level) will be horizontal or – less frequently – vertical, whereas a lesion at the mesencephalic level will usually result in vertical, torsional and – rarely – horizontal binocular nystagmus.

### b) Nystagmus resulting from inability to maintain one or both eyes in an eccentric position

Here, elastic elements try to return the eye to the primary position, resulting in the slow phase of the nystagmus, which will therefore change direction according to the position of eyes. Accordingly, there will be right horizontal nystagmus when looking to the right, left nystagmus in left gaze, up-beat nystagmus when looking up, and down-beat nystagmus in the reverse gaze direction. The inability to maintain one or both eyes in an eccentric position can result from a muscular paresis or a weakness of the neurological structures

commanding ocular muscles. When a nystagmus of this kind is binocular and conjugate, it is generally caused by a failure of the integrator of the horizontal and vertical eye movements and always corresponds to a central lesion. However, it should be kept in mind that the first cause of this failure is associated with medication (psychotropic, anti-epileptic).

### c) Nystagmus caused by visuo-motor-loop impairment

Eye fixation and pursuit result from the permanent correction of the position of the eyes to compensate for retinal slip. A change in the associated feedback loops can induce ocular oscillation or drift. The impairment of these loops can affect both perception and motor elements. This group includes congenital nystagmus, acquired pendular nystagmus and non-nystagmic eye fixation instabilities (square waves and ocular flutter, opsoclonus).

## 3. Vestibulo-ocular inhibition

This is usually evaluated with electro-nystagmography or video nystagmography but it can be also clinically tested by asking patients to stretch out their arms in front of them and to look at their thumbs while rotating the head and the arms “together”. Any inability to maintain the gaze on the thumbs is easily detected by the appearance of a nystagmus during the rotation. The diagnosis of a deficit in the inhibition of the vestibulo-ocular reflex is not always correct. It should be remembered that this immediate inhibition results from the genesis of another eye movement in the opposing direction but

at a speed identical to the slow phase of the vestibulo-ocular nystagmus.<sup>3</sup> At the speeds usually tested, a pursuit movement cancels the slow phase of the nystagmus. The inhibition will therefore be impaired if the pursuit system is failing. A central lesion could very well spare this system of eye pursuit. The correct interpretation is therefore that a deficit in vestibulo-ocular reflex inhibition signals a central lesion but the opposite is not necessarily true. The preservation of normal inhibition does not indicate that the deficit is of labyrinthine origin.

#### **4. Tilt of the visual fields (room tilt illusion)**

Patients perceive a rotation, often of 90 or 180 degrees, of the visual fields with both eyes. This rotation can occur in the three spatial planes. They are usually brief and found most commonly in brainstem<sup>4</sup> or cerebellar infarcts, in cortical lesions – more particularly during vestibular epilepsies – but also in peripheral lesions.<sup>5</sup> They are a consequence of the faulty integration of visual and otolith information. This visual tilt is rarely present simultaneously with abnormalities of the subjective vertical line because the latter is of otolith origin and can be corrected by adequate visual information.

#### **5. Visual symptoms associated with an improvement in visual refraction**

Vision contributes to balance through two mechanisms. Firstly through the analysis of the content of the visual fields, by extracting vertical or horizontal references and anticipating destabilisation

factors (obstacles, escalators). And secondly by allowing subjects to estimate their own stability. This is done by analysing the movement of the projections on the retina of fixed visual targets, or by measuring the eye movements necessary to stabilise this projection on the retina. All the factors that may interfere with the movement of the projection of fixed visual targets on the retina may therefore affect the ability of subjects to estimate their stability on the basis of visual information. The most common disruptive elements include the prismatic effect of lenses, any drastic modification of refraction, for example after cataract surgery, or ocular instabilities associated with abnormal eye movements.

Multifocal lenses merit particular attention. The correction they bring about changes with the vertical direction of the gaze. The prismatic effect, in other words the deviation of light rays caused by the curvature of the glasses, also varies according to the vertical position of the eyes. This modifies the amplitude of the compensatory eye movement for a head movement (vestibulo-ocular gain) as a function of the vertical position of the eyes. In other words, the same 10-degree movement of a visual target will require the eye to turn more than 10 degrees when focusing for close vision, and less than 10 degrees when focusing for remote vision. The stabilisation of the visual environment and the estimation of subject stability from fixed visual targets therefore becomes much more complex because the analysis has to change for every vertical position of the eyes. Although a lot of subjects quickly adapt, others never do.

Similarly, when there is a dras-

tic correction in astigmatism, there may be interference with space perception and particularly of the orientation of vertical or horizontal lines.

If subjects can estimate their own stability by analysing the eye movements required to stabilise the image on the retina, it is clear that any paresis of an ocular muscle or any modification in eye motility may induce vertigo symptoms.

#### **6. Ocular saccade impairments**

Two types of ocular saccade abnormalities are particularly significant for dizziness: saccade hypermetria and the slowing of the vertical saccades.

##### **a) Saccade hypermetria**

Saccades are fast and precise movements. These two characteristics make them particularly sensitive to dysfunction in several structures of the brainstem. In particular, lesions in the cerebellar system will impair the precision and sometimes also the speed of the saccades. This loss of saccade precision will appear as saccade amplitudes that are either too weak (hypometric) or too strong (hypermetric). Although dysfunctions in many structures involved in saccade programming can produce hypometria, saccade hypermetria is almost specific to lesions of the cerebellar vermis. Other median cerebellar structures control vestibulo-ocular reflex gain and play an essential role in balance. Hypermetric saccades against a background of vertigo or dizziness are therefore strongly suggestive of the presence of a cerebellar

syndrome. For mechanical reasons associated with the orbit, the probability of detecting hypermetric saccades is doubled when we test the precision of centripetal saccades, in other words when the gaze moves from an eccentric position, returning to the primary position. Clinical diagnosis involves asking patients to target alternately one finger situated between 20 and 30 degrees laterally and the second situated in front of them. The clinician will look for the eyes overshooting each target, followed by a corrective saccade. These hypermetric movements are easily recognisable on saccade recordings in so far as the saccades are unpredictable in terms of amplitude and position, preventing the progressive improvement of precision by anticipating saccades with the same amplitude.

#### b) Slowing of vertical saccades

A vestibular otolithic syndrome is frequently the consequence of an ischaemic lesion in the terminal territory of brainstem arteries. The lesion is situated in the sub-thalamic region, and extends up to the midbrain. This mesencephalic extension is responsible for the otolithic syndrome, which is often associated with a slowing of the vertical saccades, without any abnormality in horizontal saccades. The pre-nuclear structures specifically involved in the realisation of vertical saccades (mesencephalic reticular formation and, in particular, the rostral interstitial nucleus of the median longitudinal fasciculus) are

near the otolithic afferences of oculomotor nuclei. When the vertical eye misalignment related to the otolithic deficit is clear in the acute phase, the slowing of the vertical saccades may be the only remaining sign several months after the sub-thalamic lesion. This deficit is easily highlighted by simply asking the patient to switch as quickly as possible between two targets (for example the index fingers of the examiner) located one above the other.

### 7. The subjective visual vertical

The subjective visual vertical (SVV) of a subject is the angle between the physical vertical line (gravitational axis) and the position of a visual linear mark adjusted vertically by the subject. This SVV is probably built up on the basis of sensory vestibular, visual and proprioceptive information which include abdominal sensors. Other perceptions such as the dynamic moments of inertia may also contribute. The subjective visual vertical is not an indicator of the postural vertical (the body axis when a subject thinks he/she is vertical), because the importance of sensory information in the estimation of these two vertical references is different. This explains the discrepancies found between postural deviation and the SVV. The sensitivity of the otolithic organs to gravity suggests that they play an essential role in the estimation of the physical vertical axis orientation. Visual information may, however, modify this perception. The effective use of these otolithic and visual data for postural control does indeed imply a correction relative

to the position of the head with regard to the trunk, and the different segments of the body in space. Cervical somaesthetic information, cutaneous, muscular and articular data are therefore needed to estimate the orientation of the physical vertical axis correctly.

The SVV relates only to the visual representation of the vertical axis and is measured in the absence of any visual reference. It seems particularly dependent on the position of the head in space and does not seem to be very sensitive to variations in the position of the cervical column or the body [data submitted for publication]. In binocular measurements, the SVV is less sensitive to eye torsions induced by oculomotor paresis, even though a binocular approach can also reduce its sensitivity to some cases of otolithic dysfunction. With methods of this kind, the SVV can be considered to be an otolithic evaluation. The SVV is frequently impaired after labyrinthic lesions, lesions of the vestibular nerve or vestibular pathways in the brainstem and in the cortical vestibular areas.

The distribution of the normal values obtained for binocular SVV measurements with the head straight using a glowing bar moving in rigorously controlled darkness (Vertical Test) in 81 subjects shows a deviation greater than  $2.8^\circ$  in fewer than 5% of normal subjects.<sup>6</sup>

### 8. Visual dependence and visual vertigo

Vision contributes to the preservation of balance, not only by allowing us to detect and anticipate obstacles or irregularities in the ground but, in particular, by supplying vertical and horizontal

references which contribute to the adjustment of our perception of the physical vertical. Finally, movements in the projections of fixed visual targets on the retina, or the eye movements needed to stabilise this projection, allow us to estimate and therefore correct our own stability. Problems arise when this visual strategy is used in circumstances where the available visual information is not appropriate.<sup>7</sup> If most of the visual field is occupied by mobile elements, or if all fixed visual landmarks are taken away, the subject must be able to disregard this visual information and use vestibular or somesthetic information more to control balance. The use of visual information in these conditions will not allow subjects to turn or stabilise themselves correctly in space, and often lead to a sensation of nausea as a result of the activation of the alarm system (parabrachialis nucleus - limbic cerebral cortex system). This persistence in the use of inadequate visual information can be the result of a vestibular deficit or a loss of the ability to select an adequate source of sensory information. This can persist in spite of the recovery of normal vestibular function, when a subject has got used to controlling balance with a visual strategy. Vestibular rehabilitation can be used in an attempt to help these patients regain the ability to select adequate sensory information.

### 9. Dynamic visual acuity

The dynamic visual acuity (DVA) test is a method for measuring the clinical functioning of the vestibulo-ocular reflex. This test measures visual acuity during horizontal sinusoidal head rotations of

at least 2 Hz and greater than 120°/second, which exceeds the limits at which it is possible to prevent compensation with anticipatory slow eye movements and catch-up saccades.

The subjects are asked to identify symbols or letters on a visual acuity chart. This is continued on successive lines until the subject misses three of the five optotypes on a line.

This is done under two conditions: head stationary (static binocular visual acuity - SVA), and with the head being passively rotated sinusoidally, 15° from centre to the left and right, to the beat of a metronome at 2 Hz (dynamic visual acuity - DVA).

A difference greater than two lines between SVA and DVA constitutes a failure score.

This test has been shown to be sensitive for vestibular impairment in adults<sup>8</sup> and children.<sup>9</sup> The results of the study of Rine *et al.*<sup>9</sup> indicate that the clinical DVA test is a reliable and valid test of gaze stability in children, and can be used to screen for vestibular hypofunction in children as young as three years of age.

### 10. Migraine and vertigo

Vertigo has been found to occur significantly more frequently in patients with migraine than in control subjects. The international classification of migraines (IHS) includes the symptom "vertigo" only as an aura of a basilar migraine. This aura has to consist of at least two of a number of symptoms, including: vertigo, tinnitus, dysarthria, binocular visual symptoms in the nasal and temporal fields, hearing loss, diplopia, ataxia, bilateral paraesthesia, bilateral paresis or a decline of the

consciousness level. However, clinical practice suggests that the link between vertigo and migraine is much more frequent, being found outside the group of patients who fulfil these criteria, and that vertiginous monosymptomatic aura is common.

Neuhauser *et al.*<sup>10</sup> assess the prevalence of migrainous vertigo in patients with migraine and in patients with vertigo according to two different diagnoses.

The diagnosis of *definite migrainous vertigo* was based on the following criteria:

1. Episodic vestibular symptoms of at least moderate severity (rotational vertigo, other illusory self or object motion, positional vertigo, head motion intolerance, *i.e.*, sensation of imbalance or illusory self or object motion that is provoked by head motion)
2. Migraine according to the IHS criteria
3. At least one of the following migrainous symptoms during at least two vertiginous attacks: migrainous headache, photophobia, phonophobia, visual or other auras
4. Other causes ruled out by appropriate investigations

A separate diagnostic category of *probable migrainous vertigo* was chosen for patients who did not entirely fulfil the above criteria for migrainous vertigo but were still considered to have migrainous vertigo as the most likely diagnosis.

The diagnosis of probable migrainous vertigo was based on the following criteria:

1. Episodic vestibular symptoms of at least moderate severity (rotational vertigo, other

### ABNORMAL EYE MOVEMENTS in ADULTS

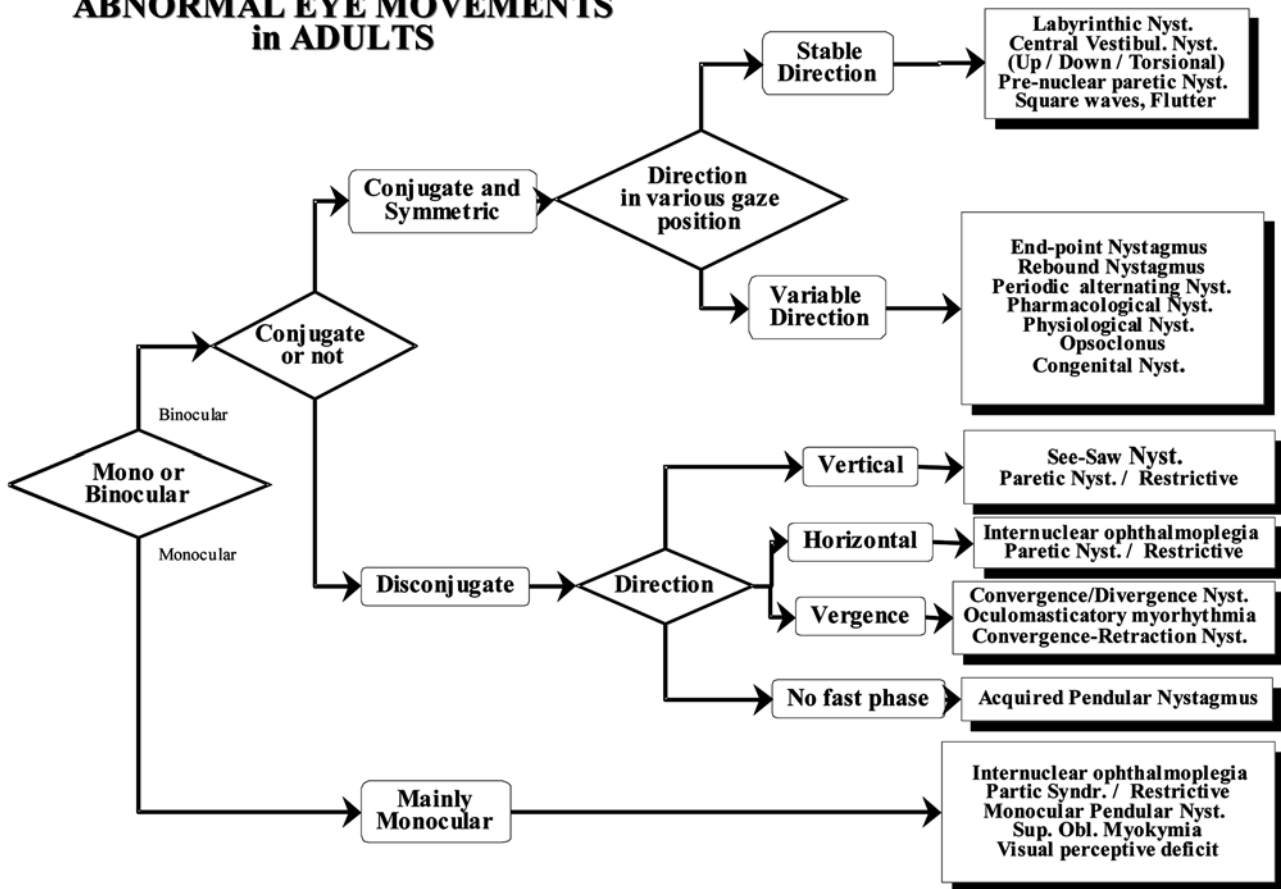


Figure 1

illusory self or object motion, positional vertigo, head motion intolerance)

2. At least one of the following: migraine according to the criteria of the IHS; migrainous symptoms during vertigo; migraine-specific precipitants of vertigo, e.g., specific foods, sleep irregularities, hormonal changes; response to anti-migrainous drugs
3. Other causes ruled out by appropriate investigations

Vestibular symptoms were defined as “mild” if they did not interfere with daily activities, “moderate” if they interfered with but did not impede daily activities, and “severe” if patients could not continue daily activities.

The results of this study show that the prevalence of migraine according to the IHS criteria was higher in the dizziness clinic group (38%) compared with the age- and sex-matched control group (24%,  $p < 0.01$ ). The prevalence of migrainous vertigo was 7% in the dizziness clinic group, and 9% in the migraine clinic group. In 16 of 33 patients, vertigo occurred both with and without headache, and in two patients headache and vertigo never occurred together. The duration of attacks varied from minutes to days.

Moreover, Dieterich *et al.*<sup>11</sup> have effectively treated migrainous patients with vertiginous aura who do not fulfil the criteria for basilar migraine, as well as migrainous patients suffering vertigo without

any headaches, and patients with recurring dizziness and without a history of the usual signs of migraine.

Benign paroxysmal vertigo in childhood is also included in the IHS classification of migraine. The criteria are:

1. Episodes of vertigo or disequilibrium without hearing loss or tinnitus
2. Accompanied by visual flashing, nausea/vomiting, pallor, agitation and ataxia. Headache not a usual feature
3. First decade of life, commonly at ages of one to four years
4. Duration: usually minutes, sometimes hours
5. Positive family history of migraine, and many develop

**ABNORMAL EYE MOVEMENTS  
in INFANTS**

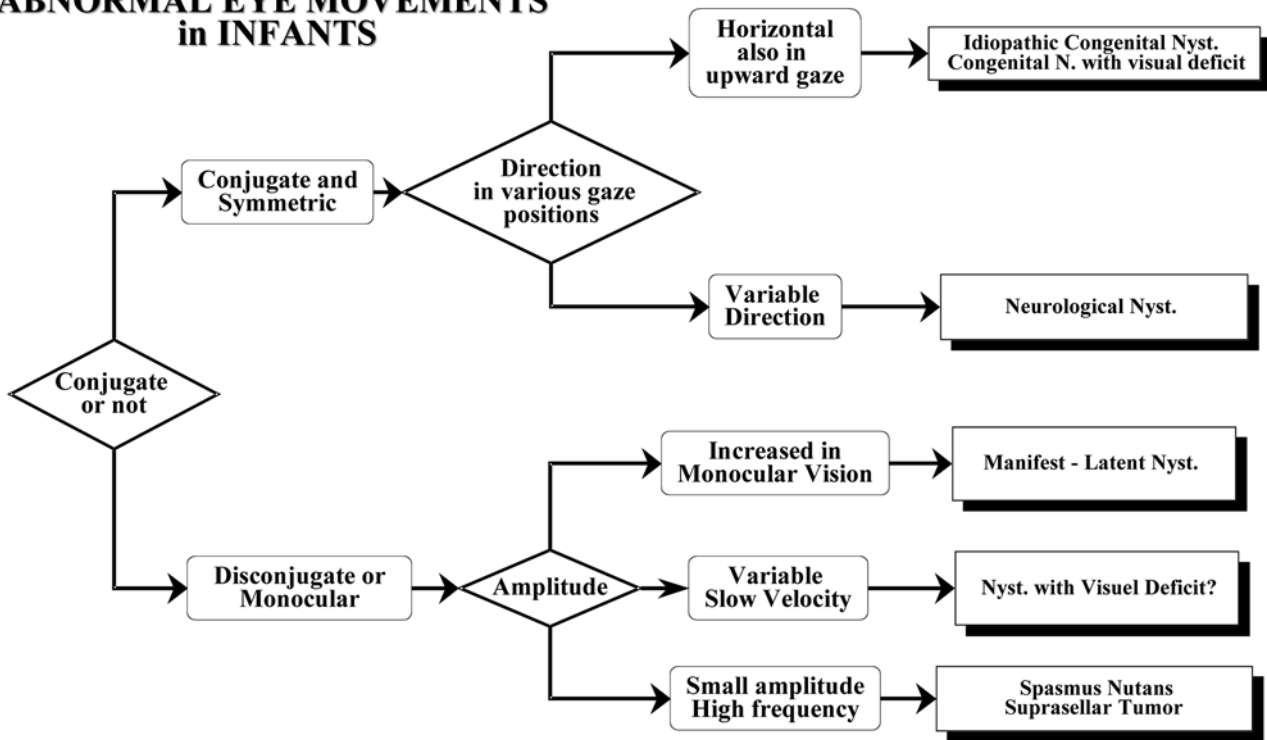


Figure 2

migraine with aura at older ages

- 6. Other causes ruled out. Differential diagnosis: Ménière's disease, vestibular epilepsy, perilymphatic fistula, posterior fossa tumours and psychogenic disorders

**11. The Claude Bernard Horner syndrome**

The interruption of the orthosympathetic eye fibres is known as Claude-Bernard-Horner syndrome (CBH). It is characterised by ipsilateral ptosis consecutive to the denervation of the Müller superior eyelid muscle and also by a discreet rise of the lower eyelid caused by denervation of its retractor muscle. In addition this syndrome includes anisocoria with ipsilateral miosis. The anisocoria may be moderate and not exceed 1/2-1 mm. It is clearer in

half-light. The anhydrosis of the ipsilateral hemi-face present in CBH syndromes of central origin is not obvious. It is often transitional because it is compensated by denervation hypersensitivity to circulating adrenergic substances. The diagnosis can be confirmed by eye-drop tests from ophthalmologists (cocaine test followed by the hydroxy-amphetamine test). At the ponto-medullar level, the orthosympathetic fibres pass just inside the vestibular nuclei. There is therefore a high probability that a lesion of the vestibular nucleus is associated with CBH syndrome. Only larger lesions will result in the classic syndrome of Wallenberg. The presence of CBH signs can still indicate a central origin months after a vestibular deficit.

In a post-traumatic context, CBH syndrome can result from the impairment of the orthosym-

pathetic fibres at the level of the cervical cord or in the pathway along the carotid arteries. We should also bear in mind that a CBH syndrome can result from a migraine crisis and this can also lead to dizziness and vertigo.

**12. Facial sensitivity deficit**

In the brainstem, post-synaptic pain sensitivity fibres of the trigeminal nerve extend down to the first cervical levels. They constitute the downward root of the trigeminal nerve and reach the upper spinal cord. At the bulbar level, these fibres are situated just inside vestibular nuclei. They are a part of the same vascular territory as the vestibular nuclei, and are irrigated by the terminal branches of the antero-inferior cerebellar artery. Other branches of the same artery irrigate the internal ear. A sensory deficit of the face

associated with acute dizziness indicates the presence of a lesion at the level of the floor of the fourth ventricle, associated or not with a labyrinthine lesion. Since topography is inverted in this downward root of the trigeminal nerve, it is mostly in the upper part of the face that we find the sensory deficit related to such a lesion.

### 13. Transient visual obscurations (Visual “Eclipses”)

Transient visual obscurations are brief moments of binocular darkening of the vision. They are found in 68% of patients suffering from idiopathic intracranial hypertension<sup>12</sup> but also in cases of orthostatic hypotension, and secondary intracranial hypertension.

### 14. Oscillopsia

These are not specific and can result from all acquired nystagmus, decompensated congenital nystagmus, non-nystagmic eye

oscillations, superior oblique myokimia and spasmus nutans.

An overview of abnormal eye movement in adults and in infants is given in Figures 1,2.<sup>13</sup>

### References

1. Brandt T, Dieterich M. Pathological eye-head coordination in roll: tonic ocular tilt reaction in mesencephalic and medullary lesions. *Brain*. 1987;110:649-666.
2. Zee DS, Leigh RJ. Disorders of eye movements. *Neurol Clin*. 1983;1:909-928.
3. Van Nechel C. Visual suppression of vestibular nystagmus. *Acta otorhinolaryngol Belg*. 1998;52:1-8.
4. Tiliket C, Ventre-Dominey J, Vighetto A, Grochowicki M. Room tilt illusion. A central otolith dysfunction. *Arch Neurol*. 1996;53:1259-1264.
5. Malis DD, Guyot JP. Room tilt illusion as a manifestation of peripheral vestibular disorders. *Ann Otol Rhinol Laryngol*. 2003;112:600-605.
6. Van Nechel C, Toupet M., Bodson I. The subjective visual vertical. *Adv Otorhinolaryngol*. 2001;58:77-87.
7. Guerraz M, Yardley L, Bertholon P, et al. Visual vertigo: symptom assessment, spatial orientation and postural control. *Brain*. 2001;124:1646-1656.
8. Tian JR, Shubayev I, Demer JL. Dynamic visual acuity during passive and self-generated transient head rotation in normal and unilaterally vestibulopathic humans. *Exp Brain Res*. 2002;142:486-495.
9. Rine RM, Braswell J. A clinical test of dynamic visual acuity for children. *Int J Pediatr Otorhinolaryngol*. 2003; 67:1195-1201.
10. Neuhauser H, Leopold M, von Brevern M, Arnold G, Lempert T. The interrelations of migraine, vertigo, and migrainous vertigo. *Neurology*. 2001;56:436-441.
11. Dieterich M, Brandt T. Episodic vertigo related to migraine (90 cases): vestibular migraine? *J Neurol*. 1999; 246:883-892.
12. Giuseffi V, Wall M, Siegel PZ, Rojas PB. Symptoms and disease associations in idiopathic intracranial hypertension (pseudotumor cerebri): a case-control study. *Neurology*. 1991;41:239-244.
13. Van Nechel C. Nystagmus spontané et mouvements oculaires anormaux. In: GEV, ed. *Vertiges 2000*. Masson, Paris; 2000:3-20.

Dr. C. Van Nechel  
Service de Réhabilitation Neurologique  
CHU Brugmann  
Place Van Gehuchten 4  
B-1020 Bruxelles, Belgium  
E-mail: cvnechel@ulb.ac.be